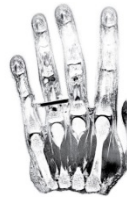

International Day of Radiology 2014
Interview on brain imaging
Ecuador / Dr. Edison Cevallos Valencia



**INTERNATIONAL
DAY OF
RADIOLOGY**
AN INITIATIVE OF THE ESR, ACR AND RSNA

The ESR spoke to Dr. Edison Cevallos Valencia, neuroradiologist for the OMNISCAN group (Ophtalmic Clinic), Los Valles Hospital and Hospifuturo (Axxis Hospital Project) in Quito, Ecuador, about the wide-ranging applications of imaging in neurology.

European Society of Radiology: Imaging is known for its ability to detect and diagnose diseases. What kind of brain diseases can imaging help to detect and diagnose?

Edison Cevallos Valencia: Imaging must not only have optimal quality but also be an ensemble of well-chosen tools to detect and diagnose brain disease. Imaging must be supported by cutting-edge technology: positron emission tomography (PET), single-photon emission computed tomography (SPECT), magnetic resonance imaging (MRI, either 1.5T or 3T), computed tomography (CT, either 64 or 128 slices), and, more conventionally, ultrasound and digital x-ray.

In addition, MRI offers functional techniques such as diffusion, perfusion, spectroscopy and tractography. That said, clinical information about the patient is very important and helps to interpret images, in addition to support from both the technician and the radiologist. Nearly 100% of brain diseases can be detected and diagnosed with radiology, thanks especially to functional techniques.

ESR: How useful is imaging in brain disease management? Does it improve the understanding of disease or improve patient prognosis?

ECV: Thanks to all the currently available diagnostic imaging techniques, we have learned a lot about the characteristics, imaging signs and pathological correlation of brain disease. We now understand them very well and can deduce patient prognosis.

ESR: What kind of technology and techniques do radiologists use to image the brain? Are there any specific techniques for particular diseases?

ECV: Technological advances made by engineers and physicists are extraordinary in all fields of imaging: digital radiology, 3D or 4D ultrasound, multislice CT, high Tesla MRI, etc. These advances have enabled radiologists to create images of the brain that have optimal resolution, and in which anatomy and behaviour in densities and signals both in brain parenchyma and vascular structures are perfectly depicted. In addition we have gained knowledge of brain metabolites (with spectroscopy), subcortex (tractography), water movement at the micro-molecular level (diffusion and apparent diffusion coefficient values), neovascularisation (perfusion) and brain functional characteristics.

Some protocols help to better observe brain structures such, as the hippocampus, in refractory complex partial seizures. Ideally, the radiologist should be present with the technician during image acquisition, to choose the most adequate sequences.

ESR: What is the difference between a radiologist and a radiographer? Who else is involved in performing brain imaging exams?

ECV: The neuroradiologist is a medical doctor who specialises in general radiology and subspecialises in neuroradiology. He or she must know how the equipment works and its physical properties. The radiographer specialises in technological management of the imaging equipment. Their collaboration and the participation of the whole team (engineers, physicists, secretaries and the administrative staff) result in optimal service in brain disease diagnosis.

ESR: Access to modern imaging equipment is important for brain imaging. Are hospitals in your country equipped to provide the necessary exams?

ECV: Public hospitals in the main populated cities are equipped with multislice CT and a few have MR scanners; but the radiological and technical staff are not the best yet. Public and private hospitals far from the capital are less equipped and have reduced access to CT and MRI studies.

ESR: In many countries there are waiting lists for MRI exams. How long can patients typically expect to wait for an exam in Ecuador?

ECV: In private hospitals waiting times vary between 48 and 72 hours. In public hospitals they vary between 15 and 30 days, approximately.

ESR: As the global population gets older, the risk of developing neurocognitive and neurodegenerative disorders increases. How can imaging help to tackle this issue?

ECV: Imaging could help through governmental and private programmes that facilitate access to the best technology for medical and paramedical staff, using these tools for accurate diagnosis and follow-up of such disorders.

ESR: Some imaging techniques, like x-ray and CT, use ionising radiation. What risk does this radiation pose to the patient and what kind of safety measures are in place to protect the patient?

ECV: We use the as low as reasonably achievable (ALARA) principle in all necessary studies, compare with previous examinations, use the programmes that are incorporated with the equipment and that calculate the radiation dose, and we use protection measures for the patient and the people who accompany them.

It undoubtedly plays a very important role in diagnosis and follow-up control; CT and MRI are the methods of choice in brain pathology detection.


ESR: In general, patients don't see the radiologist. A patient will discuss the image with the neurologist, neurosurgeon or oncologist. When they ask a question, they're often told: "I'm not a radiologist". Why don't radiologists discuss the image with the patient first?

ECV: Standardised patient care does not entail direct contact with patients. Radiologists only very rarely have direct contact with patients, mainly because of their heavy workload. Patients and their families are not always prepared to assess their pathology adequately, so communication between the radiologist and the referring doctor is often preferred, preferably in written form and occasionally on the phone.

ESR: How expensive are radiological examinations to the health service and is there a risk that some of these examinations could be blocked by health technology assessment agencies deeming them to be not cost-effective? If so, how can patients help to ensure that these examinations are made available?

ECV: Imaging examinations are free in public hospitals. In private practice, CT and MRI costs vary according to the financial resources of the patient: patients coming from public hospitals will pay 110 dollars, those coming from foundations will pay 135, and those coming from private institutions will pay 199 dollars per examined anatomic region. Injecting contrast product increases the cost of the examination by 70 to 90%.

Patients have access to almost all examinations in both public and private hospitals; cooperation agreements exist between the latter and between public institutions and foundations if healthcare authorities decide so.



Edison Ramiro Cevallos Valencia is a neuroradiologist for the OMNISCAN group (Ophthalmic Clinic), Los Valles Hospital and Hospifuturo (Axxis Hospital project) in Quito, Ecuador. He trained at the Central University in Quito, Ecuador, Chile University in Santiago de Chile, and Javeriana University in FINC Bogotá, Colombia.

He specialises in MR (1.5T and 3T) and multislice CT (16 and 64 slices) of the brain, skull base, face, neck and spine. He is part of the docent group for postgraduate residents in radiology at the Central University. He has written several articles on central nervous system imaging for many local scientific journals and has presented several of his papers at congresses of the Iberian-Latino American Neuroradiology Society and the Neurosurgery College in Ecuador and Venezuela.